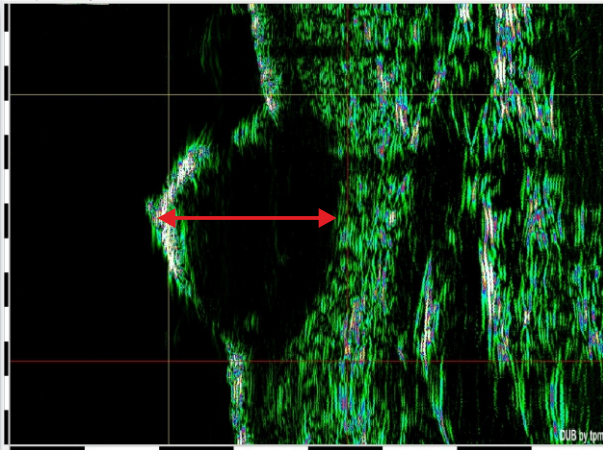


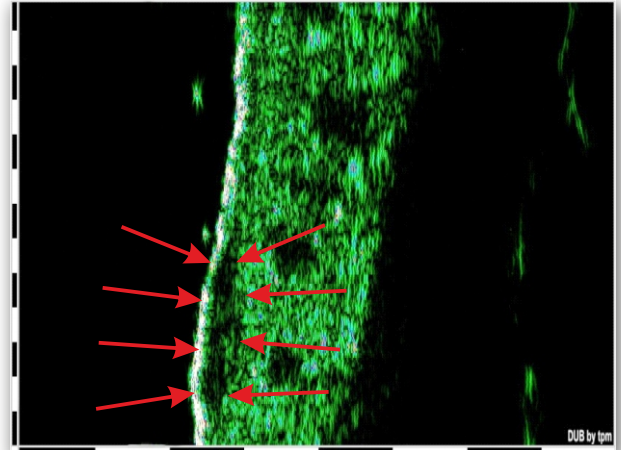
Fields of Application

■ Basal cell carcinoma - 22 MHz



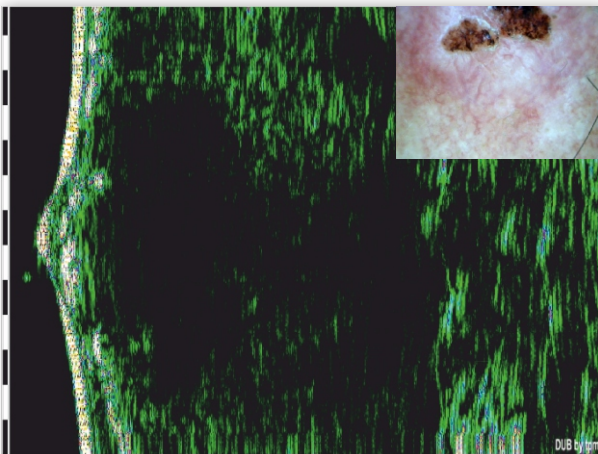
Nodular basal cell carcinoma, good visible hypoechoic tumor area with 2.6 mm depth

■ Basal cell carcinoma - 22 MHz



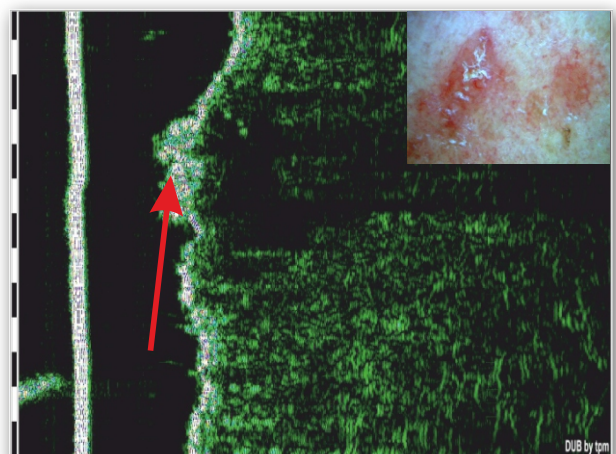
Superficial basal cell carcinoma, intraepidermal or subdermal hypoechoic band of 0.6 mm depth

■ Squamous cell carcinoma - 22 MHz

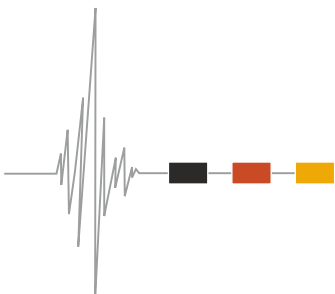


Nonuniform epidermis thickness, hypoechoic focus in dermis.

■ Actinic ceratosis - 75 MHz



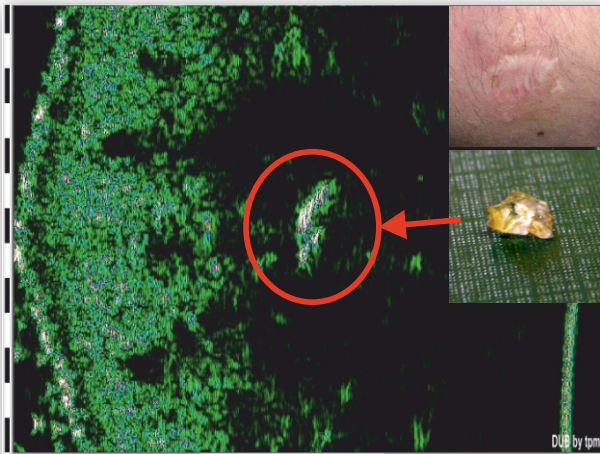
Increased epidermis thickness, low ultrasound density of the dermis within depths of 50 to 1000 µm.



Dermatology

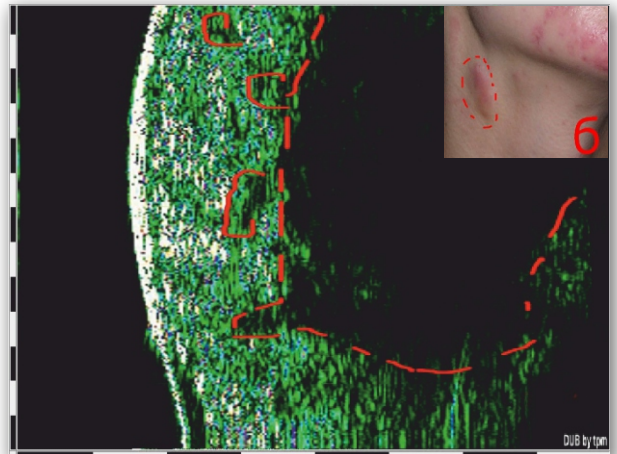
Fields of Application

■ Foreign body in scar tissue - 75 MHz



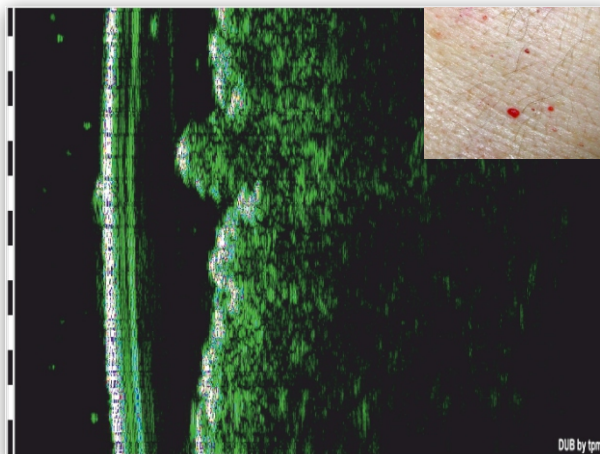
Inside of hypertrophic scar at 1700 μm depth focus with extremely high ultrasound density >150 . The piece of glass was extracted from scar tissue.

■ Actinomycosis - 22 MHz



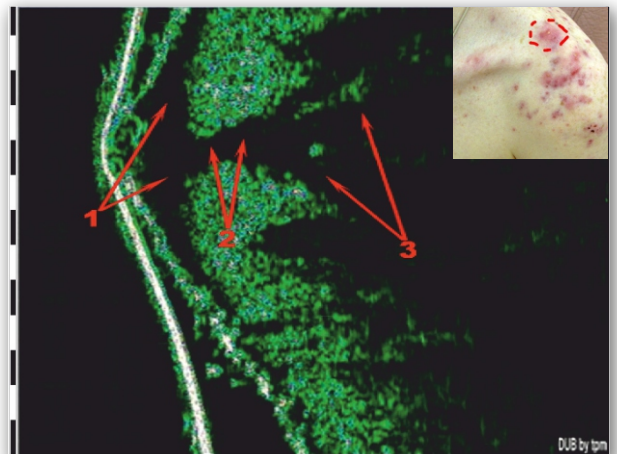
Echonegative inflammatory infiltrate on the border-line of dermis and hypodermis.

■ Capillary hemangioma - 22 MHz



Hypoechoic zone, protruding 300-400 μm over intact skin, depth of rear contour 500-700 μm .

■ Acne conglobata - 75 MHz



There are two cavities: (1) upper cavity, (2) transdermal fistula, (3) subdermal infiltrate.

