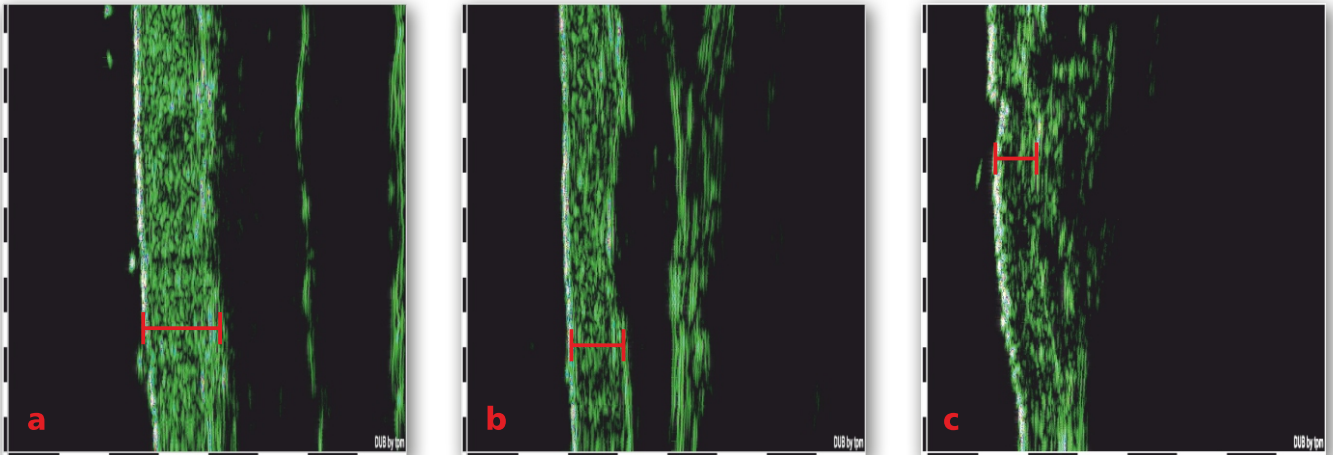


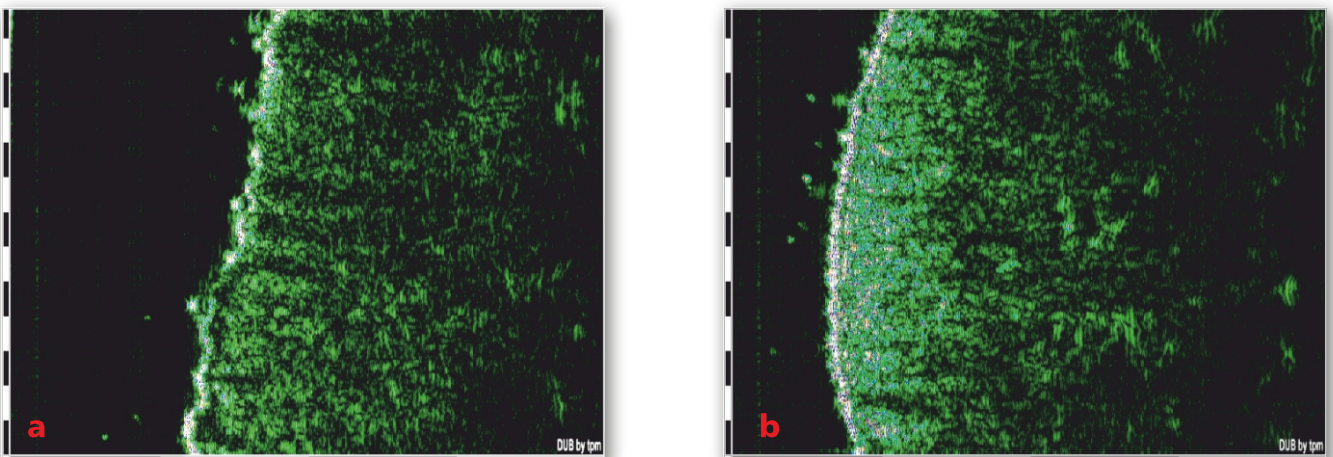
Fields of Application

■ Skin aging - 22 MHz




Scans of normal skin dorsum of the hand from patients aged (a) 28 years, (b) 45 years and (c) 80 years. There is a consistent reduction of the thickness and the ultrasound density of the dermis and epidermis.

■ Fractional laser photothermolysis - 75 MHz



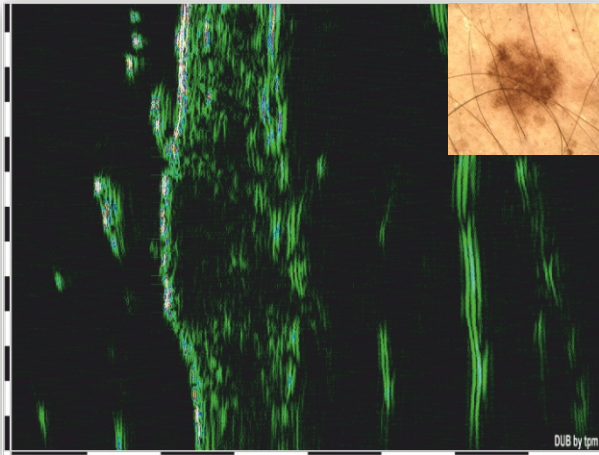
Scans of forehead skin from 30 years old patient. (a) shows the skin before fractional photothermolysis and (b) shows the same area after 12 months. There is a significant increase of ultrasound density of the dermis within 50 to 300 µm depth.



Aesthetics

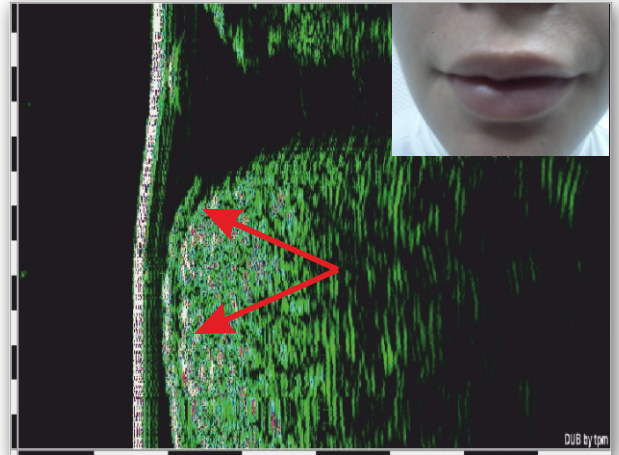
Fields of Application

■ Pigmented naevus - 22 MHz




Size 4 x 4.5 mm, protruding 200 µm over intact skin, hypoechoic focus in dermis up to 500 µm depth.

■ Side effect after filler injection - 22 MHz



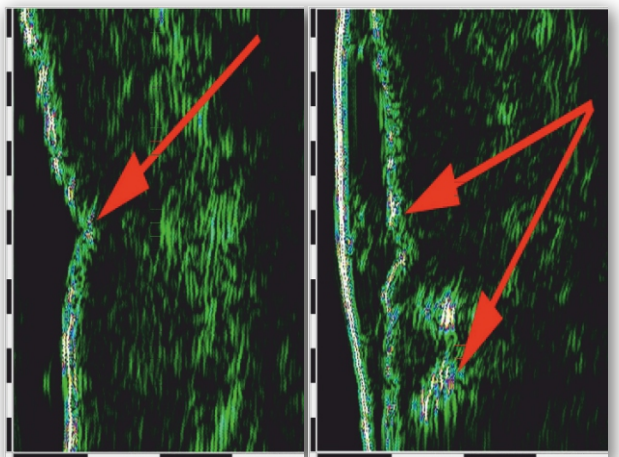
Fibrosis inside of upper lip after cross-linked HA injection.

■ Distribution of cross-linked HA - 75 MHz



Normal distribution (red oval) of HA 3 days after injection into the dermis.

■ Wrinkle correction - 22 MHz



Wrinkle on forehead skin
(a) wrinkle depth before correction: 350-400 µm
(b) after correction (ridupuncture): hyperechogenic parts corresponding to needle electrode micro-treks. Skin relief was partially restored.

